



CORRESPONDENCE COVID-19 CASES

Coagulopathy and Antiphospholipid Antibodies in Patients with Covid-19

April 8, 2020

DOI: 10.1056/NEJMc2007575

[Metrics](#)

To rapidly communicate information on the global clinical effort against Covid-19, the Journal has initiated a series of case reports that offer important teaching points or novel findings. The case reports should be viewed as observations rather than as recommendations for evaluation or treatment. In the interest of timeliness, these reports are evaluated by in-house editors, with peer review reserved for key points as needed.

We describe a patient with Covid-19 and clinically significant coagulopathy, antiphospholipid antibodies, and multiple infarcts. He was one of three patients with these findings in an intensive care unit designated for patients with Covid-19. This unit, which was managed by a multidisciplinary team from Peking Union Medical College Hospital in the Sino–French New City Branch of Tongji Hospital in Wuhan, China, was set up on an emergency basis to accept the most critically ill patients during the outbreak of Covid-19. Severe acute respiratory syndrome coronavirus 2 (SARS-CoV-2) infection was confirmed in all the patients by reverse-transcriptase–polymerase-chain-reaction (RT-PCR) assay or serologic testing.

A 69-year-old man with a history of hypertension, diabetes, and stroke presented with fever, cough, dyspnea, diarrhea, and headache. Covid-19 was diagnosed in the patient on January 25, 2020, on the basis of RT-PCR testing that detected SARS-CoV-2. The initial treatment was supportive; however, the illness subsequently progressed to hypoxemic respiratory failure warranting the initiation of invasive mechanical ventilation.

Table 1.

Table 1. Demographic and Clinical Characteristics and Laboratory Findings.*

Characteristic	Patient 1	Patient 2	Patient 3
Demographic characteristics			
Age — yr	69	65	70
Sex	Male	Female	Male
Initial findings			
Medical history	Hypertension, diabetes, stroke	Hypertension, diabetes, coronary artery disease, no history of thrombosis	Hypertension, emphysema, nasopharyngeal carcinoma, stroke
Symptoms at disease onset	Fever, cough, dyspnea, diarrhea, headache	Fever, cough, dyspnea	Fever, fatigue, dyspnea, headache
Imaging features	Ground-glass opacity, bilateral pulmonary infiltrates	Ground-glass opacity, bilateral pulmonary infiltrates	Bilateral pulmonary infiltrates
Treatment before admission to ICU	Oseltamivir, intravenous immune globulin	Antibiotics	Antibiotics, ribavirin, rosuvastatin
Days from disease onset to thrombotic event	18	33	10
Findings on admission to ICU			
Days since disease onset	24	21	24
Disease severity	Critical	Critical	Critical
Laboratory findings			
White-cell count (per mm ³)	17,790	6730	8710
Differential count (per mm³)			
Total neutrophils	16,290	6230	7090
Total lymphocytes	430	290	790
Total monocytes	800	170	430
Platelet count (per mm ³)	78,000	79,000	180,000
Hemoglobin (g/liter)	111	99	92
Albumin (g/liter)	26.3	32.6	24.4
Alanine aminotransferase (U/liter)	15	11	8
Aspartate aminotransferase (U/liter)	23	20	20
Lactate dehydrogenase (U/liter)	632	233	417
Creatinine (μmol/liter)	80	58	86
Creatine kinase (U/liter)	63	335	16
EGFR (ml/min/1.73 m ²)	86.6	93.2	78.5
High-sensitivity cardiac troponin I (pg/ml)	3876.8	14.3	125.4
Prothrombin time (sec)	17.0	17.2	15.1
Activated partial-thromboplastin time (sec)	43.7	45.3	47.6
Fibrinogen (g/liter)	4.15	4.42	6.42
Fibrin degradation products (mg/liter)	85.5	8.1	7.3
D-dimer (mg/liter)	>21.00	2.84	3.23
Serum ferritin (μg/liter)	ND	2207.8	ND
Procalcitonin (ng/ml)	0.11	0.18	0.40
High-sensitivity C-reactive protein (mg/liter)	112.0	56.0	125.4
Antiphospholipid antibodies	Anticardiolipin IgA, anti-β ₂ -glycoprotein I IgA and IgG	Anticardiolipin IgA, anti-β ₂ -glycoprotein I IgA and IgG	Anticardiolipin IgA, anti-β ₂ -glycoprotein I IgA and IgG
Imaging features	Multiple cerebral infarctions in bilateral frontal parietal occipital lobe and bilateral basal ganglia, brain stem, and bilateral cerebellar hemispheres	Multiple cerebral infarctions in right frontal and bilateral parietal lobe	Multiple cerebral infarctions in frontal lobe, right frontal parietal temporal occipital lobe, and bilateral cerebellar hemispheres

* EGFR denotes estimated glomerular filtration rate, ICU intensive care unit, and ND not determined.

Demographic and Clinical Characteristics and Laboratory Findings.

On examination, the patient had evidence of ischemia in the lower limbs bilaterally as well as in digits two and three of the left hand. Computed tomographic imaging of the brain showed bilateral cerebral infarcts in multiple vascular territories. Pertinent laboratory results on admission of the patient (Patient 1) to the intensive care unit are summarized in [Table 1](#). They included leukocytosis, thrombocytopenia, an elevated prothrombin time and partial thromboplastin time, and elevated levels of fibrinogen and D-dimer. Subsequent serologic testing showed the presence of anticardiolipin IgA antibodies as well as anti-β₂-glycoprotein I IgA and IgG antibodies.

Two other patients with similar findings were seen at the specialized intensive care unit for patients with Covid-19 at Tongji Hospital. Serologic tests in these patients were positive for anticardiolipin IgA antibodies as well as anti- β_2 -glycoprotein I IgA and IgG antibodies. Further clinical details are summarized in [Table 1](#). Lupus anticoagulant was not detected in any of the patients, although testing was performed while the patients were acutely ill.

Antiphospholipid antibodies abnormally target phospholipid proteins, and the presence of these antibodies is central to the diagnosis of the antiphospholipid syndrome. However, these antibodies can also arise transiently in patients with critical illness and various infections.¹ The presence of these antibodies may rarely lead to thrombotic events that are difficult to differentiate from other causes of multifocal thrombosis in critically patients, such as disseminated intravascular coagulation, heparin-induced thrombocytopenia, and thrombotic microangiopathy.

Yan Zhang, M.D.

Meng Xiao, M.Sc.

Shulan Zhang, M.D.

Peng Xia, M.D.

Wei Cao, M.D.

Wei Jiang, M.D.

Huan Chen, M.D.

Xin Ding, M.D.

Hua Zhao, M.D.

Hongmin Zhang, M.D.

Chun Yao Wang, M.D.

Jing Zhao, M.D.

Xuefeng Sun, M.D.

Ran Tian, M.D.

Wei Wu, M.D.

Dong Wu, M.D.

Jie Ma, M.D.

Yu Chen, B.S.

Dong Zhang, M.Sc.

Jing Xie, Ph.D.

Xiaowei Yan, M.D.

Xiang Zhou, M.D.

Zhengyin Liu, M.D.
Jinglan Wang, M.D.
Bin Du, M.D.
Yan Qin, M.D.
Peng Gao, M.D.
Xuzhen Qin, M.D.
Yingchun Xu, M.D.
Wen Zhang, M.D.
Taisheng Li, M.D.
Fengchun Zhang, M.D.
Yongqiang Zhao, M.D.
Yongzhe Li, M.D.
Shuyang Zhang, M.D.
Peking Union Medical College Hospital, Beijing, China
yongzhelipumch@126.com, shuyangzhang103@163.com

Supported by grants to Dr. Yongzhe Li from the National Natural Science Foundation of China (81671618 and 81871302) and the Chinese Academy of Medical Sciences Initiative for Innovative Medicine (2017-I2M-3-001 and 2017-I2M-B&R-01).

[Disclosure forms](#) provided by the authors are available with the full text of this case at NEJM.org.

This case was published on April 8, 2020, at NEJM.org.

Dr. Yan Zhang, Mr. Meng Xiao, and Dr. Shulan Zhang and Drs. Shuyang Zhang and Yongzhe Li contributed equally to this case.

1 Reference ▾

Supplementary Material

[Disclosure Forms](#)

PDF

592KB



More about

COAGULATION

PULMONARY/CRITICAL CARE

ANTICOAGULATION/THROMBOEMBOLISM

VIRAL INFECTIONS

More from the week of April 9, 2020



CINE EDITORIAL

Audio Interview: Emerging Tools in the Fight against Covid-19

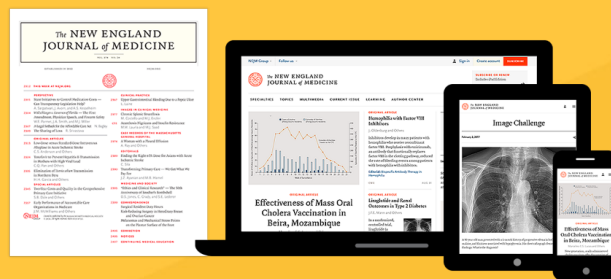
E.J. Rubin, L.R. Baden, and S. Morrissey

PERSPECTIVE

A New Era for Mind-Bl

M.L. Dossett, G.L. Fricchio

Tap into groundbreaking research and clinically relevant insights



SUBSCRIBE →

Already a subscriber? [Sign In](#) or [Renew](#)

